

## ***Anredera cordifolia* leaves extract accelerates the wound healing of normal and hyperglycemic rats**

**Gembira Arkemo Situmorang<sup>1</sup>, Zulham Yamamoto<sup>1,2\*</sup>, M. Ichwan<sup>1,3</sup>, Bambang Prayugo<sup>4</sup>**

<sup>1</sup>Master Program in Biomedical Sciences, Faculty of Medicine, Universitas Sumatera Utara  
Jl. dr. Mansyur No. 5 Medan, 20155, Indonesia

<sup>2</sup>Department of Histology, Faculty of Medicine, Universitas Sumatera Utara  
Jl. dr. Mansyur No. 5 Medan, 20155, Indonesia

<sup>3</sup>Department of Pharmacology and Therapeutics, Faculty of Medicine, Universitas Sumatera Utara  
Jl. dr. Mansyur No. 5 Medan, 20155, Indonesia

<sup>4</sup>Department of Surgery, Faculty of Medicine, Universitas Sumatera Utara  
Jl. Bunga Lau No.17 Medan, 20136, Indonesia

Submitted: 26-07-2021

Reviewed: 30-08-2021

Accepted: 11-02-2022

### **ABSTRACT**

*Anredera cordifolia* ((Madeira vein (English) or *Binahong* (Indonesia language)) leaves contain ingredients that promote wound healing. This study aims to determine the effect of *Madeira vein* leaves ethanolic extract (MLE) on normal and hyperglycemic rat wounds. This is an experimental study using male Wistar rats aged 2-3 months, body weight between 250-300 grams induced by a single injection of streptozotocin dose 60 mg/kg BW intraperitoneally. Rats were divided into 8 groups namely normal without MLE, normal with MLE 2.5% w/v, normal with MLE 5% w/v, normal with MLE 10% w/v, hyperglycemia without MLE, hyperglycemia with MLE 2.5% w/v, hyperglycemia with MLE 5% w/v and hyperglycemia with MLE 10% w/v. Punch biopsy was used to create wounds on the skin of rats with a diameter of 8 mm after the blood glucose level measurement was higher than 200 mg/dL. MLE is applied 3 times a day for 14 days on the wounds. Wound contractions occurred in line with the length of treatment days. In normal skin, the area of the wound had decreased by 22% within three days and to 76% at 14 days after wound creation. On the 14th day of treatment, the wound area of hyperglycemic rats decreased > 60%. The largest wound contraction was found when using MLE 10% w/v. Increasing the MLE dose stimulated better wound contraction/healing than control wounds. Wound healing involves many types and products of cells. Starting with hemostasis, wound healing is followed by inflammatory and proliferative phases to form new tissue, angiogenesis, and matrix formation. The MLE content is beneficial for wound healing in normal and hyperglycemic rats. MLE plays a role in accelerating wound healing in normal and hyperglycemic rats. The MLE dose of 10% w/v provides faster wound healing than the 2.5% and 5% w/v doses.

**Keywords:** *extracts, madeira vein leaves, wounds, hyperglycemia, streptozotocin*

---

**\*Corresponding author:**

Zulham Yamamoto

Department of Histology, Faculty of Medicine, Universitas Sumatera Utara

Jl. dr. Mansyur No. 5 Medan, 20155, Indonesia

E-mail: zulham@usu.ac.id



## INTRODUCTION

Wound healing in the skin is a dynamic and well-ordered process involving cellular, humoral and molecular mechanisms that begins soon after injury and can extend for years (Reinke & Sorg, 2012). Normally, wound healing consists of inflammatory, proliferative, and remodeling phases, in which each of the phases is interrelated (MacEwan et al., 2017). Rapid hemostasis, appropriate inflammation, differentiation, proliferation, and migration of mesenchymal cells to the wound site, appropriate angiogenesis, rapid re-epithelialization (regrowth of epithelial tissue over the wound surface), and proper synthesis, cross-linking, and alignment of collagen to provide strength to the healing tissue are all factors that contribute to optimal wound healing (Guo & DiPietro, 2010).

Treatment for diabetic wounds has never been satisfactory. The frequency of the complications can be reduced by controlling blood glucose level, self-examination of the feet, and routine examinations by a physician (Packer et al., 2021). Wound dressings, surgical debridement, even skin grafting, and other conventional therapies cannot offer a high-quality healing process because these treatments cannot provide the essential growth factors that can modulate the healing process (Suryanarayan et al., 2013). As a result, the cost of treating diabetic wounds and the length of treatment burden the community. People who are often hit by medical costs will turn to traditional medicine to get healing (Ismail, 2015).

Madeira vein (*Anredera cordifolia*) is often and commonly used in traditional wound care and healing (Mutiaru et al., 2015). It is easy to obtain because it also grows in Indonesia (Betriksia et al., 2018). Studies on the effects of *Madeira vein leaves ethanolic extract* (MLE) include studies on burn healing (Betriksia et al., 2018), acne vulgaris (Anwar & Soleha, 2016), and many others. The flavonoids in *Madeira vein* leaves act as broad-spectrum antibiotics. In addition, *Madeira vein* leaves have antioxidant and anti-inflammatory activities (Anwar & Soleha, 2016).

Delayed healing of wounds occurs because of persistent trauma, infection, or ischemia as well as underlying conditions such as vascular disease or diabetes (MacEwan et al., 2017). The content of chemicals in the MLE may be useful in the healing of normal and diabetic wounds. The concentration of 10% and 30% of ethanolic MLE gel were effective for wound healing in alloxan-induced diabetic ulcers in rats (Kintoko & Desmayanti, 2009). Topical use of MLE showed the potential of 10% extract in accelerating wound closure of streptozotocin (STZ)-induced diabetic rats (Kintoko et al., 2017). This study aimed to determine the effect and dose of lower concentration of topical ethanolic MLE on wound healing and contraction in normal rats and hyperglycemic rats induced by STZ.

## MATERIALS AND METHOD

### Materials

The leaves of *Anredera cordifolia* were collected from Berastagi highland, Karo regency, North Sumatera, Indonesia. The samples were identified by Herbarium Medanense (MEDA) of *Universitas Sumatera Utara* with the decree of 5128/MEDA/2020.

The laboratory animals were male Wistar rats that were bred in the Pharmacology Laboratory, Faculty of Medicine, *Universitas Sumatera Utara* (USU). All rats were 2-3 months old and weighed 250-300 g.

### Study design and ethical clearance

This study uses a true experimental method with a pretest-posttest control group design. Ethical clearance for this study was obtained from the Animal Research Ethics Committee, Faculty of Mathematics and Natural Sciences, USU with the decree of 00699/KEPH-FMIPA/2020.

### Madeira vein leaves extract

A total of 400 g of Madeira vein leaves were dried in an oven at 45°C for 24 hours. Subsequently, the Madeira vein leaves were mashed with a blender and dissolved in 1500 mL of 90% alcohol for 4 days at room temperature. After filtering with Whatman #1 filter paper, the MLE was

dried using a rotary evaporator. The solid resulting from MLE drying was weighted and dissolved with carboxymethylcellulose and water in the concentrations of 2.5%, 5%, and 10% w/v.

### Hyperglycemia induction in rats

Rats were injected intraperitoneally with STZ (32238, Nacalai Tesque) at a dose of 60 mg/kg BW in citrate buffer pH 4.5 to induce hyperglycemia. Rats in the normal (control) group only received sterile water injection intraperitoneally. Blood glucose levels (BGL) from rat tail venous blood samples were determined using a BGL meter (EasyTouch™) at 7 days post-induction of hyperglycemia. Rats were considered in hyperglycemic conditions once the BGL was higher than 200 mg/dL (Emordi et al., 2016). The bodyweight and BGL of rats were examined before hyperglycemia induction, 7 days after hyperglycemia induction, and after wound creation (day 3, day 7, day 10, and day 14) (Table 1).

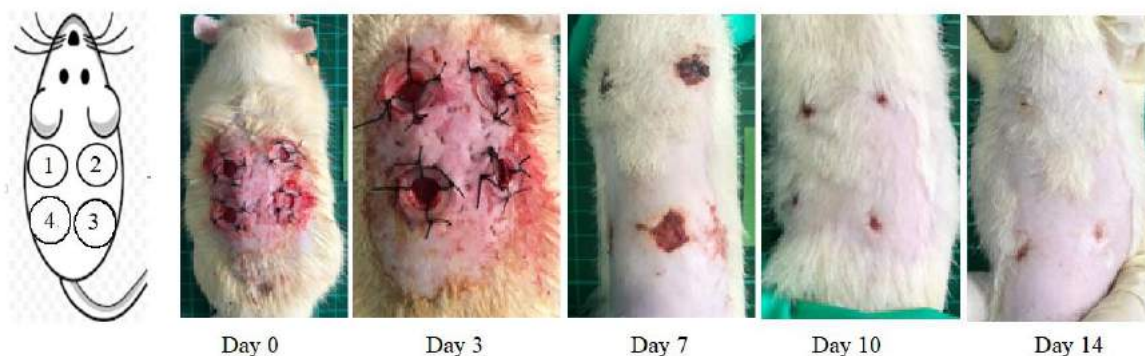**Table 1. The blood glucose level of normal and hyperglycemic rats before and after streptozotocin injection**

Groups	Blood glucose level (mg/dL)						p
	Before streptozotocin induction	7 days after streptozotocin induction					
			Day 3	Day 7	Day 10	Day 14	
Normal	111.41 ± 26.77	100.31 ± 33.91	102.63 ± 21.90	109.25 ± 13.36	104.88 ± 10.29	112.57 ± 18.07	0.65
Hyperglycemic	95.81 ± 16.26	421.89 ± 123.85	303.14 ± 119.63	355.75 ± 185.96	130.00 ± 0.00	152.00 ± 2.83	0.00*

\*= significant, one-way Anova

### Wound Creation and Treatment

Wounds were created on day 7 after hyperglycemia induction. Experimental animals were anesthetized by injection of 0.2-0.3 mL of ketamine intramuscularly. The rat hair on the back was shaved off. Subsequently, 4 wounds with a diameter of 8 mm were created on the shaved back using a sterile punch biopsy (Figure 1).



**Figure 1. Rat wounds created with punch biopsy**

After wound creation at day 0, the artificial wound healed with a sufficiently large wound contraction at day 14. The wounds in this figure were created in normal rats. Wound 1 (1) acted as a control and was applied with normal saline. Wound 2 (2), wound 3 (3), and wound 4 (4) were applied with 2.5% w/v Madeira vein leaves ethanolic extracts (MLE), 5% w/v MLE, and 10% w/v MLE, respectively. Finally, all of the wounds were dressed using a 2 cm diameter bandage. The same method was carried out when changing the wound dressing at the time of observation.

A total of 64 rats were divided into 8 groups with each group consisting of 8 rats, namely group N1 (normal without giving MLE), N2 (normal by giving MLE 2.5% w/v), N3 (normal by giving MLE

5% w/v), N4 (normal with MLE 10% w/v), H1 (hyperglycemia without MLE), H2 (hyperglycemia with MLE 2.5% w/v), H3 (hyperglycemia with MLE 5% w/v), and H4 (hyperglycemia with MLE 10% w/v). In each topical MLE application, each wound got 18 mg of MLE solution. During the treatment period, each wound received 3 applications on the wound using a new and clean applicator. The wound was then dressed using an Elastomull™ bandage with a diameter of 2 cm.

### Rat wound assessment

Determination of the wound size was carried out on day 0, day 3, day 7, day 10, and day 14. The wound areas were determined by taking pictures of the wound with a camera from a distance of 18 cm. The images acquired were processed using the Image J program. The day 0 wound images were marked with freehand selections and became the set scales assuming the day 0 wound images were perfect circles so that the day 0 wound area was 50.24 mm<sup>2</sup>. In the other wound images (from groups day 3, day 7, day 10, and day 14), the wounds were marked with freehand selections and then were analyzed using the Analyze>Measure menu for wound area based on the set scale value of the day 0 wound images. Wound contractions at day 3, day 7, day 10, and day 14 were a decline in healed wound area as measured by initial day 0 wound area.

$$\text{Wound contraction (\%)} = \frac{(\text{WD0} - \text{WDn})}{\text{WD0}} \times 100\%$$

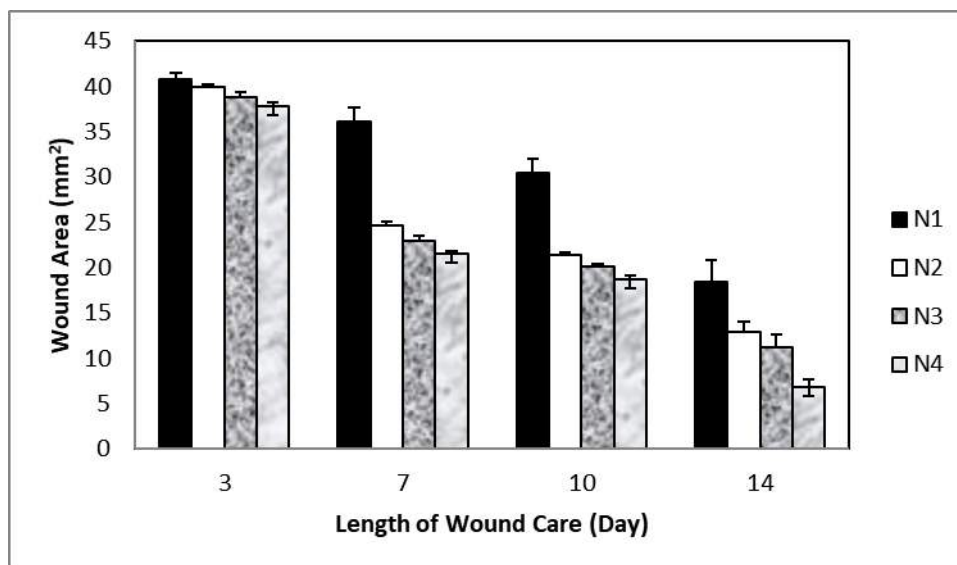
WD0 = wound area at day 0 (50.24 mm<sup>2</sup>), WDn = wound area at observation day (day 3, day 7, day 10, and day 14).

Measurement of wound area in this study can also be an alternative in assessing wound contraction. Several studies measured wound diameter as a parameter (Kintoko et al., 2017). Since there might be differences in the speed of wound healing at the edges, ImageJ may measure more accurate than calculating wound diameter.

## RESULTS AND DISCUSSION

Skin wound healing is an important physiological process involving many cells types and products in the skin (Gonzalez et al., 2016). Usually, the healing process begins with hemostasis which checks for blood loss and microbial invasion in the wound area. This phase is quickly followed and overlaps with the inflammatory phase. In the inflammatory phase, neutrophils regulate the healing process and are followed by macrophages that clear pathogens and cell debris along with cytokines, growth factors, and other cells. The proliferative phase overlaps with the inflammatory phase in which new tissue, new blood vessels (angiogenesis) and matrix formation initiates to fill the wound area. Lastly, the remodeling phase increases the tensile strength of the collagenous extracellular matrix and reduces blood supply to the healing wound area (Patel et al., 2019).

Wound area in all normal rat groups decreased with time (Figure 2). The average wound area decreased by 22% (on day 3) and by 76% (on day 14) post wound creation (Table 2). The MLE treatments groups (N2, N3, and N4) were, at first, only slightly more effective than N1 in reducing wounds area but became noticeably more effective from day 7 to day 14. MLE 10% w/v gave the best wound contraction.



**Figure 2.** Wound area in normal rats applied with various MLE concentrations for 14 days

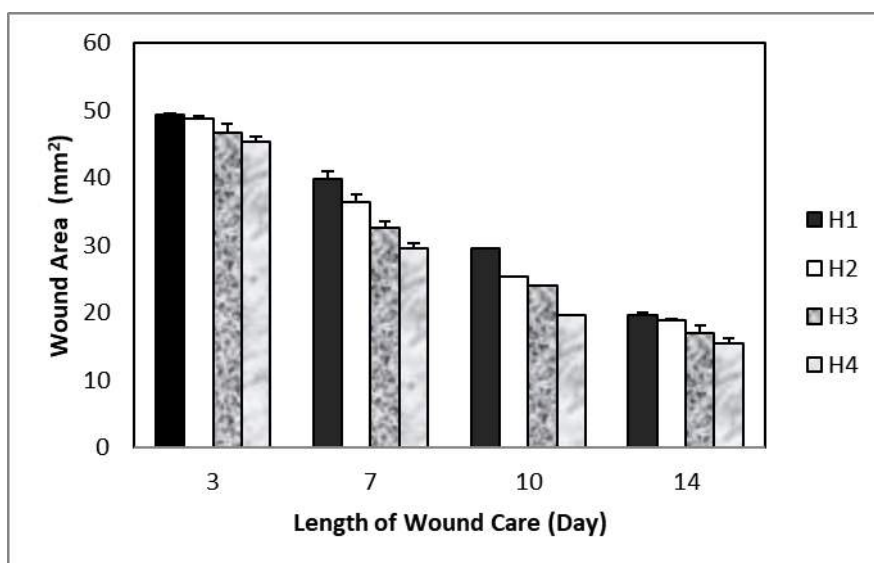
N1 is a group of normal rats without MLE, N2 is a group of normal rats given MLE 2.5% w/v, N3 is a group of normal rats given 5% w/v MLE, and N4 is a group of normal rats given MLE 10% w/v.

**Table 2.** Post-MLE treatment wound contraction against the initial wound in normal rats

Group	Wound Contraction (%)				<i>p</i>
	Day 3	Day 7	Day 10	Day 14	
N1	18.89 ± 1.39	28.18 ± 3.03	39.36 ± 0.94	63.44 ± 4.79	0.000*
N2	20.57 ± 0.72	50.92 ± 0.94	57.31 ± 0.45	74.44 ± 2.21	0.000*
N3	22.65 ± 1.01	54.40 ± 1.23	59.94 ± 0.48	77.82 ± 2.84	0.000*
N4	24.79 ± 0.79	57.21 ± 0.52	62.74 ± 0.75	86.45 ± 1.62	0.000*
<i>p</i>	0.000*	0.000*	0.000*	0.000*	

The initial wound area was 50.24 mm<sup>2</sup>. N1 is a group of normal rats without Madeira vein ethanolic extract (MLE), N2 is a group of normal rats applied with MLE 2.5% w/v, N3 is a group of normal rats applied with 5% w/v MLE, and N4 is a group of rats normal applied with MLE 10% w/v. \* = significant, one-way Anova.

Wound area in all hyperglycemic rat groups decreased with the length of treatment (Figure 3). On day 3, the wound area was not much different from the day 0 wound area with a decrease in wound area reaching 5%. Increasing the dose of MLE stimulated better contraction/wound healing than control wounds (Table 3). On day 14, the average wound area decreased >60%. The greatest wound contraction was found in the use of MLE 10% w/v.



**Figure 3. Wound area in hyperglycemic rats applied with various MLE concentrations for 14 days**

H1 is a group of hyperglycemic rats without MLE, H2 is a group of hyperglycemic rats given MLE 2.5% w/v, H3 is a group of hyperglycemic rats given 5% w/v MLE, H4 is a group of hyperglycemic rats by giving MLE 10% w/v.

**Table 3. Post-MLE treatment wound contraction against the initial wound in hyperglycemic rats**

Group	Wound Contraction (%)				<i>p</i>
	Day 3	Day 7	Day 10	Day 14	
H1	1.65 ± 0.39	20.72 ± 2.40	41.18 ± 0.00	60.92 ± 0.83	0.000*
H2	2.92 ± 0.90	27.51 ± 2.32	49.58 ± 0.00	62.49 ± 0.51	0.000*
H3	6.95 ± 2.42	35.13 ± 2.08	52.25 ± 0.00	66.36 ± 2.21	0.000*
H4	9.91 ± 1.51	41.31 ± 1.69	60.85 ± 0.00	69.27 ± 1.60	0.000*
<i>p</i>	0.000*	0.000*	N/A	0.000*	

The initial wound area was 50.24 mm<sup>2</sup>. H1 is a group of hyperglycemic rats without Madeira vein ethanolic extract (MLE), H2 is a group of hyperglycemic rats group applied with MLE 2.5% w/v, H3 is a group of hyperglycemic rats group applied with MLE 5% w/v, H4 is a group of hyperglycemic rats group applied with MLE 10% w/v. \* = significant, one-way Anova.

STZ-induced hyperglycemia in this study can be classified as new/acute hyperglycemia (within 7-21 days), and the acute hyperglycemia created delays in wound healing as compared to normal rat groups (Table 2 and 3). MLE with various phytochemicals in its content showed a role in wound healing in normal and hyperglycemic rats. An increase in the concentration of MLE also showed an acceleration in wound contraction in this study and other studies (Kintoko et al., 2017).

Acute wounds generally heal easily without any problems. The main concerns involve age-related changes in normal physiological functions such as diseases such as diabetes, obesity, impaired blood circulation, and stressful environmental conditions. Based on their healing potential, wounds are classified to be either acute or chronic wounds. Chronic wounds have no regular series of healing



stages and heal in more than 12 weeks. Diabetes delays the healing process because it interferes with each phase of wound healing (Patel et al., 2019). Diabetic wounds, either in the form of acute or chronic wounds, delayed healing and showed a persistent inflammatory phase due to inhibition of mature granulation tissue formation and decreased tensile strength of the wound. This may occur due to vascular damage resulting in ischemia (Patel et al., 2019).

The use of plant extracts in wound healing studies is quite extensive both in plant species such as Madeira vein (Kintoko et al., 2017) or other plant species (Geethalakshmi et al., 2013), extraction methods (Geethalakshmi et al., 2013), as well as preparations (Kintoko et al., 2017). Often, phytochemical screening is not carried out in the assessment of the biological activity of plant extracts (Aditia et al., 2017; Hasri et al., 2017) because the phytochemical data are available in other studies. Phytochemical screening of the ethanol extract of Madeira vein leaves showed that the extract contained alkaloids, B-sitosterol, phenolic compounds, flavonoids, saponins, and triterpenoids (Basyuni et al., 2017).

Alkaloids are a broad class of secondary chemical compounds that include a variety of elements and biomolecules that are produced from amino acids or transamination (Dey et al., 2020). Taspine, an alkaloid extracted from the Euphorbiaceae plant in Brazil, stimulates chemotaxis for fibroblasts and, depending on the dose, infiltration of mononuclear cells into the wound (Porras-Reyes et al., 1993). The ability of MLE in wound healing in this study may be similar to the mechanism of action of taspine. Unfortunately, until now, the alkaloid type of MLE has not been identified.

B-sitosterol, a member of the plant steroid family found in some plants, especially soybeans, induces rapid re-epithelialization and burn to heal (Dey et al., 2020). The biological activity of B-sitosterol is quite wide-ranging from analgesic, anti-inflammatory, antibacterial, immunomodulatory, antioxidant, antidiabetic, and antibiotic (Babu & Jayaraman, 2020). A total of 27 compounds were identified from the total flavonoid samples. The effect of total flavonoids on skin excision wounds is to increase granulation tissue, fibroblasts, and proliferation of capillaries. Therefore, flavonoids induce neovascularization, anti-inflammation, and growth factors (Pang et al., 2017).

Inflammation and oxidative stress are critical factors associated with delayed wound repair. Phenolic compounds make key contributions in accelerating various phases of wound healing, collagen formation, wound closure, and epithelialization due to their antibacterial, anti-inflammatory, and antioxidant properties. Pathogens can enter the bloodstream through injured skin areas and the severity of infection can be exacerbated by the stimulation of critical inflammatory mediators including chemokines and interleukin-8 which ultimately alter fibroblast and keratinocyte activity, collagen synthesis, and granulation tissue maturation (Yadav et al., 2018). In addition, the role of MLE as an antibacterial against *E. coli* and *S. aureus* can be achieved at a minimum inhibitory concentration of 8.5% and 8%, respectively (Hasri et al., 2017).

The ability of MLE in wound healing is also strengthened by the content of saponins. Administration of saponins from ginseng to wounds showed a higher keratinocyte migration rate, fewer inflammatory cells in the first 3 days of the wound, greater wound contraction, and higher collagen deposition than in the control group during wound healing. These results suggest a beneficial saponin effect when applied to heal skin wounds (Kim et al., 2011). Although *Madeira vein* leaves extract has been associated with fibroblast proliferation on the healing of palatal mucosal wounds (Hanafiah et al., 2019) and fibroblast cell lines (Hanafiah et al., 2019), the effect of the saponin extracted from the leaves has not been studied.

Triterpenoids, which are produced from oleanolic acid, are anti-inflammatory and angiogenesis inhibitors (Magdalena Radomska-Leśniewska et al., 2017). The triterpenoid extracted from the *Euryale ferox* shell has a therapeutic effect on insulin resistance diabetes showing regulated blood-sugar metabolism, lowering the blood sugar of hyperglycemic mice, recovering the pancreatic islet morphology, and increased insulin receptor expression in a dosed manner (Yuan et al., 2014). *In vitro*, triterpenoid has strong  $\alpha$ -glucosidase inhibitory activity by mean of noncompetitive inhibition (Liu et al., 2014). In surgical wounds, triterpenoids cause a reduction in wound closure time. Triterpenes also modulate the production of reactive oxygen species in the wound environment and accelerate the

tissue repair process. Triterpenoids also cause cell migration, cell proliferation, and collagen deposition. Unfortunately, little is known about the effects of triterpenoids on keratinocytes and fibroblasts (Agra et al., 2015). In addition, triterpenoid has effects as antifungal, hypoglycemic/antidiabetic, antimicrobial, hemolytic analgesic, and anthelmintics (Astuti et al., 2012). The effect of triterpenoids is opposite to that of  $\beta$ -sitosterol in vascular proliferation. This requires further studies related to the dosage and effects of the mixture of the two substances.

## CONCLUSION

MLE plays a role in accelerating wound healing in normal and hyperglycemic rats with the dose of MLE 10% w/v giving faster wound healing than the doses of 2.5% and 5% w/v.

## ACKNOWLEDGEMENT

The authors thank *Universitas Sumatera Utara* for the Talenta Research Grant under the Master Thesis Research Scheme for Fiscal Year 2020 with the decree number: 28/UN5.2.3.1/PPM/SPP-TALENTA USU/2020 which has financed this study.

## REFERENCES

- Aditia, D. S., Hidayat, S. T., Khafidhoh, N., Suhartono, S., & Suwondo, A. (2017). Binahong leaves (*Anredera cordifolia* Tenore Steen) extract as an alternative treatment for perineal wound healing of postpartum mothers. *Belitung Nursing Journal*, 3(6), 778–783. <https://doi.org/10.33546/bnj.290>
- Agra, L. C., Ferro, J. N. S., Barbosa, F. T., & Barreto, E. (2015). Triterpenes with healing activity: A systematic review. *Journal of Dermatological Treatment*, 26(5), 465–470. <https://doi.org/10.3109/09546634.2015.1021663>
- Anwar, A. M., & Soleha, T. U. (2016). Benefit of Binahong's Leaf (*Anredera cordifolia*) as a treatment of *Acne vulgaris*. *Majority*, 5(4), 179–183
- Astuti, S. M., Sakinah, A. M. M., & Risch, A. (2012). The Triterpenoid Saponin from Binahong [*Anredera cordifolia* (Ten) Steenis] to Potential Using as Antidiabetic Activity in Animal Laboratory. *Proceeding of International Conference on Drug Development of Natural Resources*, 331–343
- Babu, S., & Jayaraman, S. (2020). An update on  $\beta$ -sitosterol: A potential herbal nutraceutical for diabetic management. *Biomedicine & Pharmacotherapy*, 131, 110702. <https://doi.org/10.1016/j.biopha.2020.110702>
- Basyuni, M., Ginting, P. Y. A. B., & Lesmana, I. (2017). *Phytochemical analysis of Binahong (Anredera Cordifolia) leaves extract to inhibit In Vitro growth of Aeromonas Hydrophila*. 020072. <https://doi.org/10.1063/1.5011929>
- Betriksia, D., Syahrial, I., & Suyatmiatun, L. (2018). Uji potensi ekstrak daun Binahong (*Anredera cordifolia* (Ten.) Steenis) terhadap peningkatan ketebalan jaringan Granulasi dan waktu penyembuhan luka bakar Tikus. *Journal of Pharmacy Science and Practice*, 5(1), 11–17.
- Dey, P., Kundu, A., Kumar, A., Gupta, M., Lee, B. M., Bhakta, T., Dash, S., & Kim, H. S. (2020). Analysis of alkaloids (indole alkaloids, isoquinoline alkaloids, tropane alkaloids). In *Recent Advances in Natural Products Analysis* (pp. 505–567). Elsevier. <https://doi.org/10.1016/B978-0-12-816455-6.00015-9>
- Emordi, J. E., Agbaje, E. O., Oreagba, I. A., & Iribhogbe, O. I. (2016). Antidiabetic and hypolipidemic activities of hydroethanolic root extract of *Uvaria chamae* in streptozotocin induced diabetic albino rats. *BMC Complementary and Alternative Medicine*, 16(1), 468. <https://doi.org/10.1186/s12906-016-1450-0>
- Geethalakshmi, R., Sakravarthi, C., Kritika, T., Arul Kirubakaran, M., & Sarada, D. V. L. (2013). Evaluation of antioxidant and wound healing potentials of *Sphaeranthus amaranthoides* Burm.f. *BioMed Research International*, 2013, 1–7. <https://doi.org/10.1155/2013/607109>



- Gonzalez, A. C. de O., Costa, T. F., Andrade, Z. de A., & Medrado, A. R. A. P. (2016). Wound healing - A literature review. *Anais Brasileiros de Dermatologia*, 91(5), 614–620. <https://doi.org/10.1590/abd1806-4841.20164741>
- Guo, S., & DiPietro, L. A. (2010). Factors affecting wound healing. *Journal of Dental Research*, 89(3), 219–229. <https://doi.org/10.1177/0022034509359125>
- Hanafiah, O. A., Abidin, T., Ilyas, Syafrudin, Nainggolan, Marline, Syamsudin, & Endang. (2019). Healing activity of Binahong (*Anredera cordifolia* (Ten.) Steenis) Leaves Extract towards NIH-3T3 Fibroblast Cells. *Journal of International Dental and Medical Research*, 12(3), 854–858.
- Hasri, Anwar, M., & Karim, M. (2017). Analisis fenolik dan daya hambat daun binahong (*Anredera cordifolia* (ten.) Steenis) terhadap bakteri *Escherichia coli* dan *Staphylococcus aureus*. *Indonesian Chemistry and Application Journal*, 1(1), 1. <https://doi.org/10.26740/icaj.v1n1.p1-9>
- Ismail, I. (2015). Faktor yang mempengaruhi keputusan masyarakat memilih Obat tradisional di gampong lam ujong. *Idea Nursing Journal*, VI(1), 7–14.
- Kim, Y.-S., Cho, I.-H., Jeong, M.-J., Jeong, S.-J., Nah, S.-Y., Cho, Y.-S., Kim, S.-H., Go, A.-R., Kim, S.-E., Kang, S.-S., Moon, C.-J., Kim, J.-C., Kim, S.-H., & Bae, C.-S. (2011). Therapeutic effect of total Ginseng Saponin on Skin Wound Healing. *Journal of Ginseng Research*, 35(3), 360–367. <https://doi.org/10.5142/jgr.2011.35.3.360>
- Kintoko, K., & Desmayanti, A. (2009). The effectivity of ethanolic extract of binahong leaves (*anredera cordifolia* (tenore) steen) gel in the management of diabetic wound healing in aloxan-induced rat models. *Jurnal Kedokteran Dan Kesehatan Indonesia*, 7(5), 227–236. <https://doi.org/10.20885/JKKI.Vol7.Iss5.art9>
- Kintoko, K., Karimatulhaji, H., Elfasyari, T. Y., Ihsan, E. A., Putra, T. A., Hariadi, P., Ariani, C., & Nurkhasanah, N. (2017). Effect of diabetes condition on topical treatment of Binahong leaf fraction in wound healing process. *Majalah Obat Tradisional*, 22(2), 103. <https://doi.org/10.22146/tradmedj.27921>
- Liu, X., Zhu, L., Tan, J., Zhou, X., Xiao, L., Yang, X., & Wang, B. (2014). Glucosidase inhibitory activity and antioxidant activity of flavonoid compound and triterpenoid compound from *Agrimonia Pilosa* Ledeb. *BMC Complementary and Alternative Medicine*, 14(1), 12. <https://doi.org/10.1186/1472-6882-14-12>
- MacEwan, M. R., MacEwan, S., Kovacs, T. R., & Batts, J. (2017). What makes the optimal wound healing material? A review of current science and introduction of a synthetic nanofabricated wound care scaffold. *Cureus*. <https://doi.org/10.7759/cureus.1736>
- Magdalena Radomska-Leśniewska, D., Bałan, B. J., & Skopiński, P. (2017). Angiogenesis modulation by exogenous antioxidants. *Central European Journal of Immunology*, 42(4), 370–376. <https://doi.org/10.5114/ceji.2017.72804>
- Mutiara, PI, G., Nurdiana, N., & Utami, Y. W. (2015). Efektifitas hidrogel Binahong (*Anredera cordifolia* (Ten.) Steenis) terhadap penurunan jumlah Makrofag pada penyembuhan luka Fase Proliferasi Tikus Putih (*Rattus norvegicus*) Galur Wistar kondisi Hiperglikemia. *Majalah Kesehatan FKUB*, 2(1), 29–40.
- Packer, C. F., Ali, S. A., & Manna, B. (2021). *Diabetic Ulcer*. In StatPearls. StatPearls Publishing. <http://www.ncbi.nlm.nih.gov/pubmed/29763062>
- Pang, Y., Zhang, Y., Huang, L., Xu, L., Wang, K., Wang, D., Guan, L., Zhang, Y., Yu, F., Chen, Z., & Xie, X. (2017). Effects and mechanisms of total flavonoids from *Blumea balsamifera* (L.) DC. on Skin Wound in Rats. *International Journal of Molecular Sciences*, 18(12), 2766. <https://doi.org/10.3390/ijms18122766>
- Patel, S., Srivastava, S., Singh, M. R., & Singh, D. (2019). Mechanistic insight into diabetic wounds: Pathogenesis, molecular targets and treatment strategies to pace wound healing. *Biomedicine & Pharmacotherapy*, 112, 108615. <https://doi.org/10.1016/j.biopha.2019.108615>
- Porrás-Reyes, B. H., Lewis, W. H., Roman, J., Simchowit, L., & Mustoe, T. A. (1993). Enhancement of wound healing by the alkaloid taspine defining mechanism of action. *Experimental Biology and Medicine*, 203(1), 18–25. <https://doi.org/10.3181/00379727-203-43567>

- Reinke, J. M., & Sorg, H. (2012). Wound repair and regeneration. *European Surgical Research*, 49(1), 35–43. <https://doi.org/10.1159/000339613>
- Suryanarayan, S., Budamakuntala, L., Suresh, D., & Sarvajnamurthy, S. (2013). Autologous platelet rich plasma in chronic venous ulcers: Study of 17 cases. *Journal of Cutaneous and Aesthetic Surgery*, 6(2), 97. <https://doi.org/10.4103/0974-2077.112671>
- Yadav, E., Singh, D., Yadav, P., & Verma, A. (2018). Antioxidant and anti-inflammatory properties of *Prosopis cineraria* based phenolic rich ointment in wound healing. *Biomedicine & Pharmacotherapy*, 108, 1572–1583. <https://doi.org/10.1016/j.biopha.2018.09.180>
- Yuan, H., Meng, S., Wang, G., Gong, Z., Sun, W., & He, G. (2014). Hypoglycemic effect of triterpenoid-rich extracts from *Euryale ferox* shell on normal and streptozotocin-diabetic mice. *Pakistan Journal of Pharmaceutical Sains*, 27(4), 859–864.